

Neurological Examination for the Dental Practitioners

Chong-hao Zhao, MD, PhD

American Board of Neurology

Subspecialty Board of Headache Medicine

American Board of Pain Medicine


American Board of Medical Acupuncture

California Permit for X-Ray Fluoroscopy Supervisor and Operator

Medical Director



California Headache & Pain Center
201 S. Buena Vista Street, # 238
Burbank, CA 91505
www.CHPCI.COM



Advanced Pain Center
1234 S. Garfield Avenue, # 205
Alhambra, CA 91801
WWW.APC-LA.COM

Components of Neurological Examination

- Mental Status
- Cranial Nerves
- Motor
- Coordination
- Reflexes
- Sensory
- Gait



Mental Status

- Check for orientation x 3
 - time
 - place
 - person



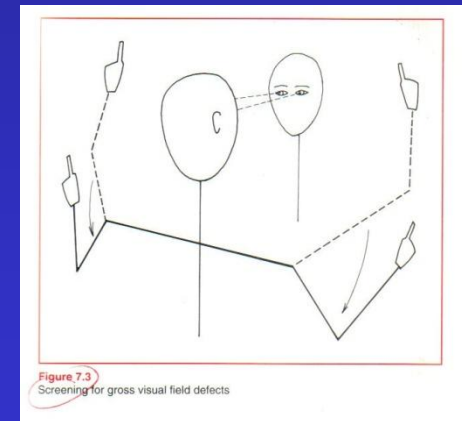
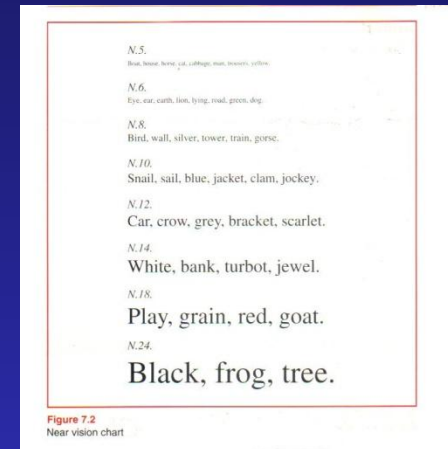
Cranial Nerve 1

- Olfactory nerve:
 - Smelling of vinegar
 - Usually skip this test
 - Skull base lesion



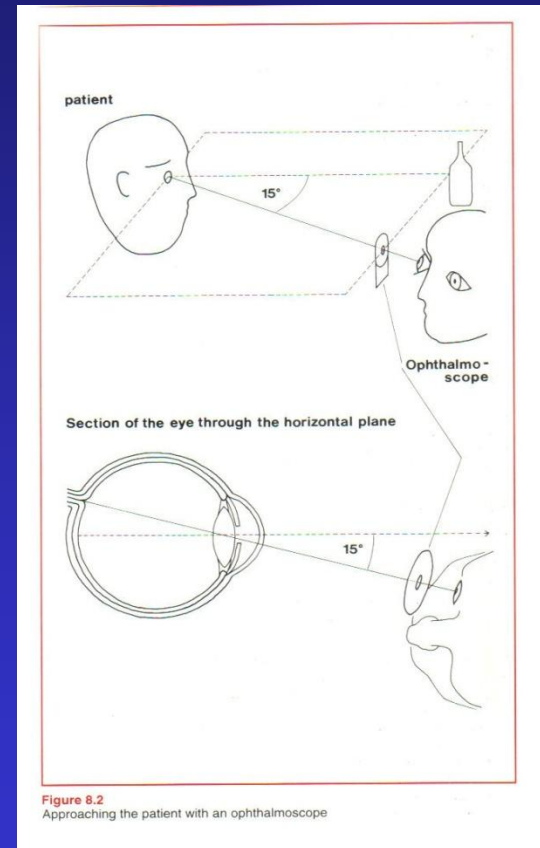
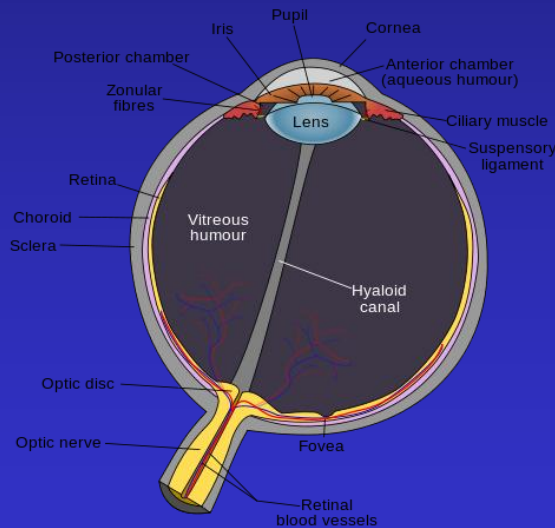
Cranial Nerve 2

- Optic nerve:
 - Visual acuity: with eyeglasses if needed, one eye at one time, using the “near card”
 - Visual field: Look at examiner’s nose, 50 cm apart, 30 cm above followed by 30 cm below patient’s eye level. Examiner waves the index finger.
 - Fundus: Papilledema, optic disk pallor



Approaching the Patient with an Ophthalmoscope

- The optic disc is 3 to 4 mm to the nasal side of the fovea

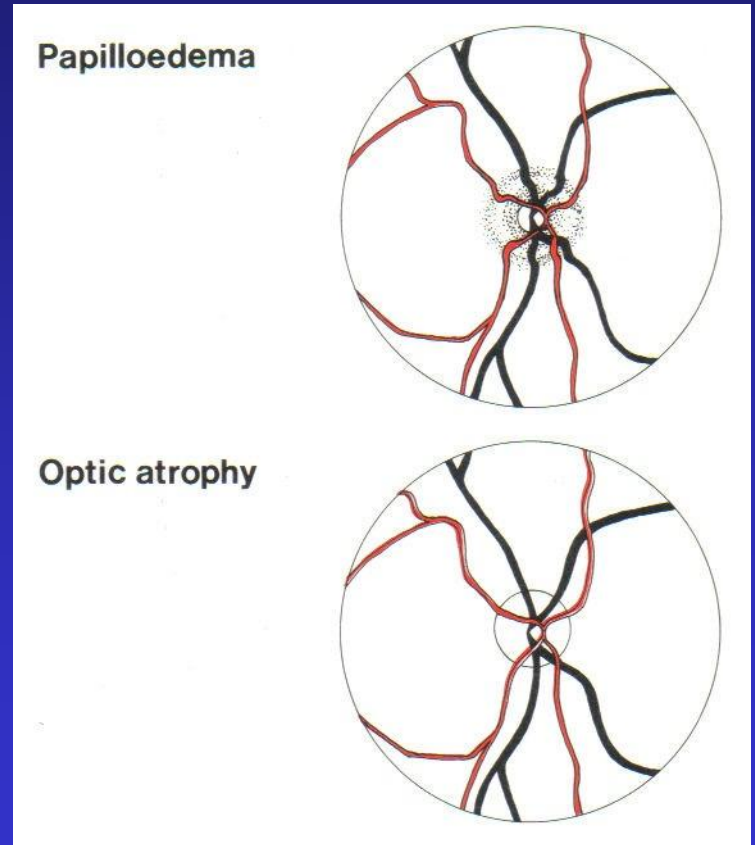
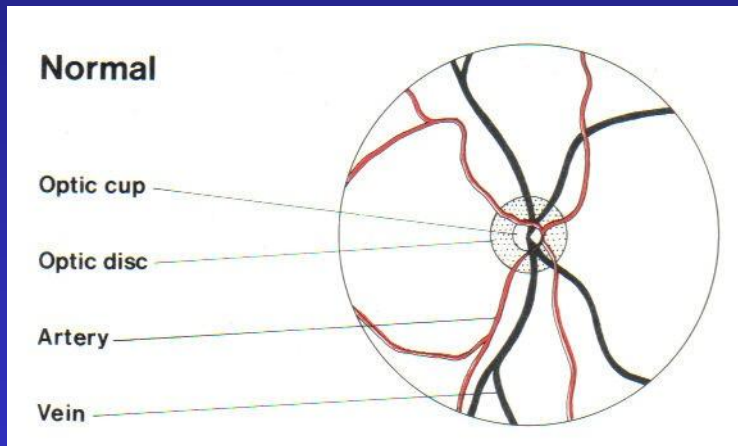


Start 30 cm away, 15 degree from the line of patient's eye fixation at the same horizontal plane of the eye, approach until within 1-2 cm of patient's eye



Fundus Appearance

Intracranial hypertension

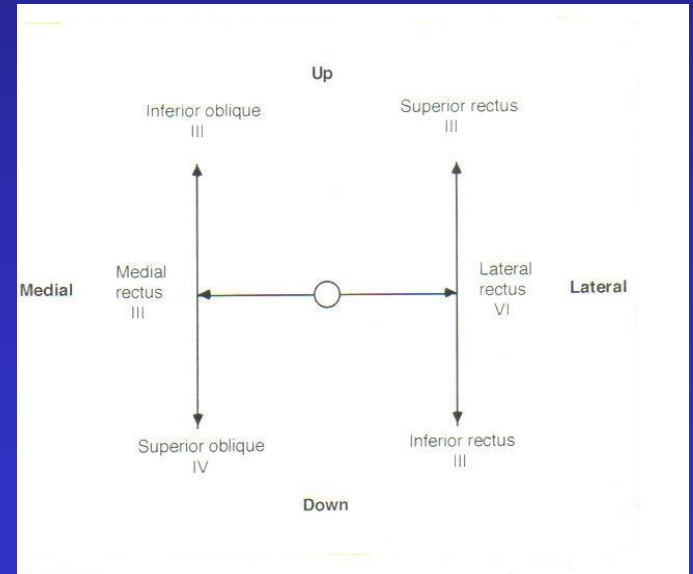


Optic neuropathy, pale disc,
e.g. optic neuritis



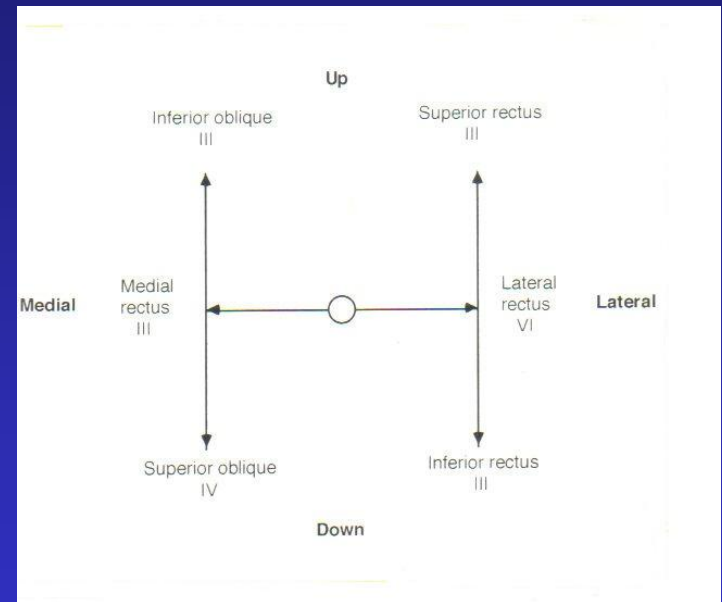
Cranial Nerve 3

- Oculomotor nerve:
 - Eyelids: look for drooping eyelid (levator palpebrae muscle)
 - Pupils (sphincter pupillae muscle)
 - Shape and symmetry: equal size?
 - Reactivity to light: Using the swinging flashlight test (optic nerve sense the light, oculomotor nerve constrict the pupils)
 - Extraocular movements: to fixate on and follow examiner's finger in all directions of gaze (inferior and superior rectus, medial rectus, inferior oblique)



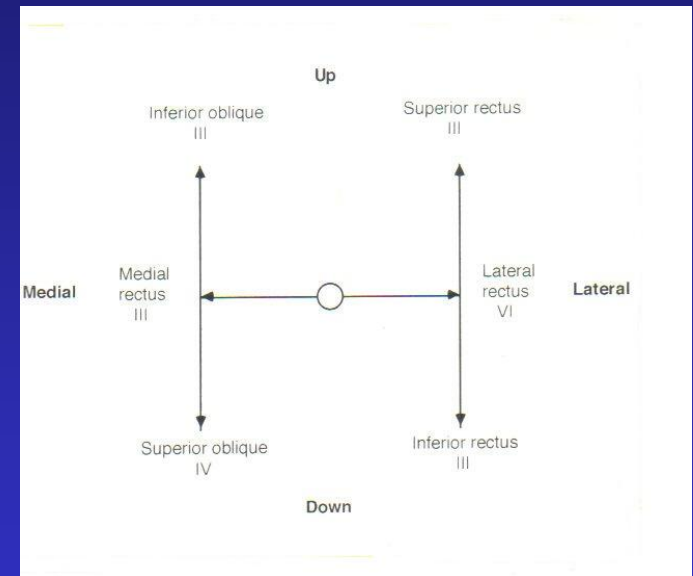
Cranial Nerve 4

- Trochlear nerve:
 - Superior oblique muscle
 - Depression and intortion of the eye ball. Lesion causes inferomedial gaze palsy)



Cranial Nerve 6

- Abducens nerve:
 - Lateral rectus muscle
 - Lateral gaze
 - Lateral gaze palsy raises the suspicion of increased intracranial pressure (e.g. pseudotumor cerebri, exerting downward pressure on the brainstem, causing the nerve to stretch along the clivus which is posterior to the sphenoid sinus.)



CN 3,4,6 – Extraocular Eye Movement

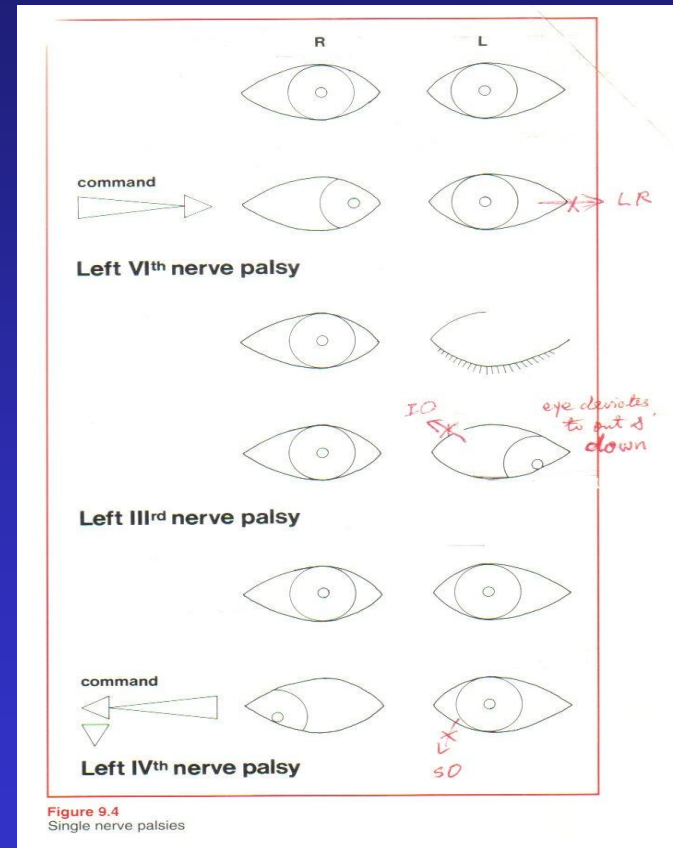
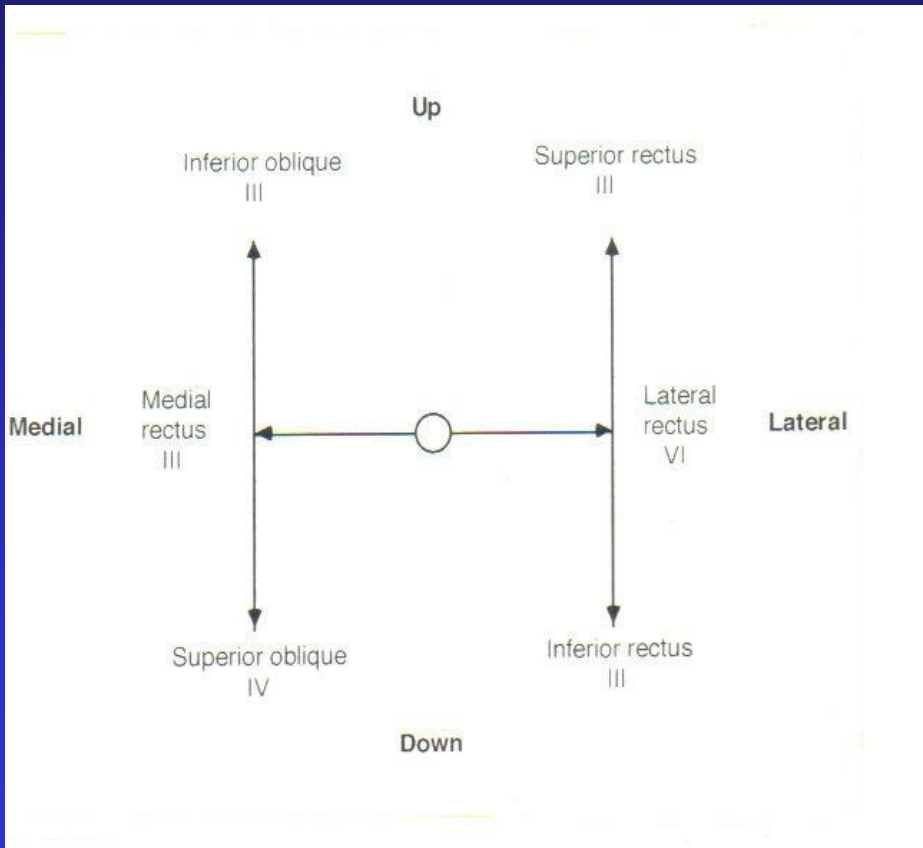


Figure 9.4
Single nerve palsies

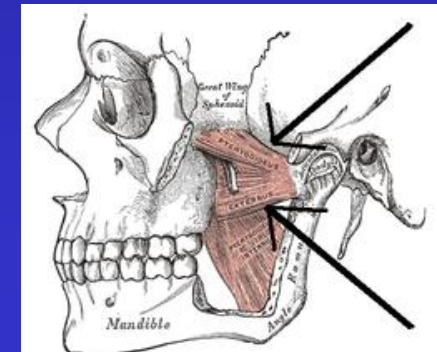
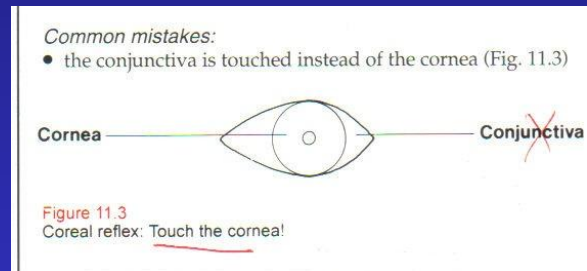
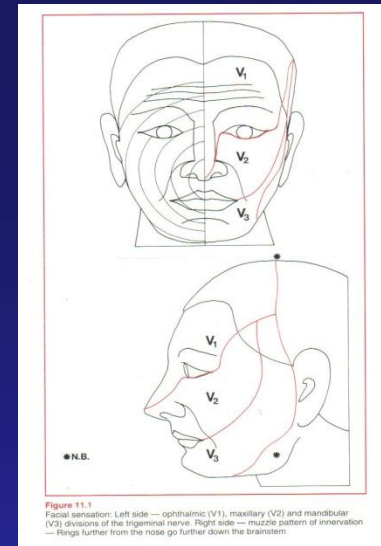


Property of Chonghao Zhao, MD, PHD

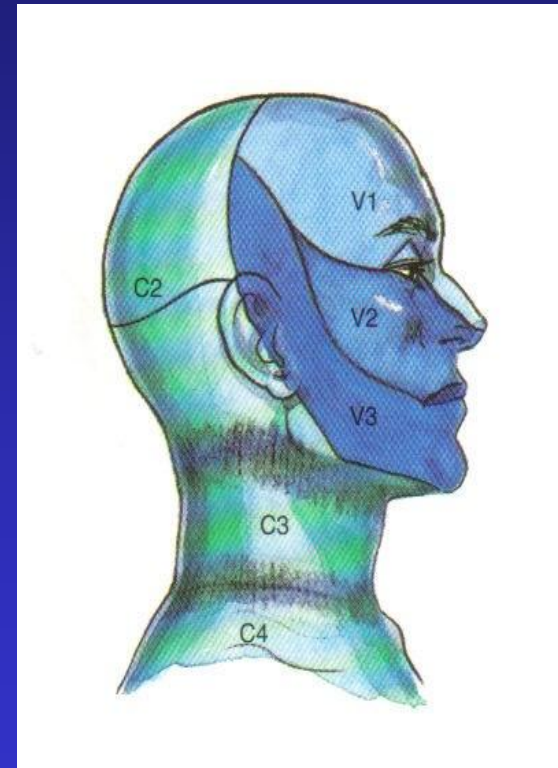
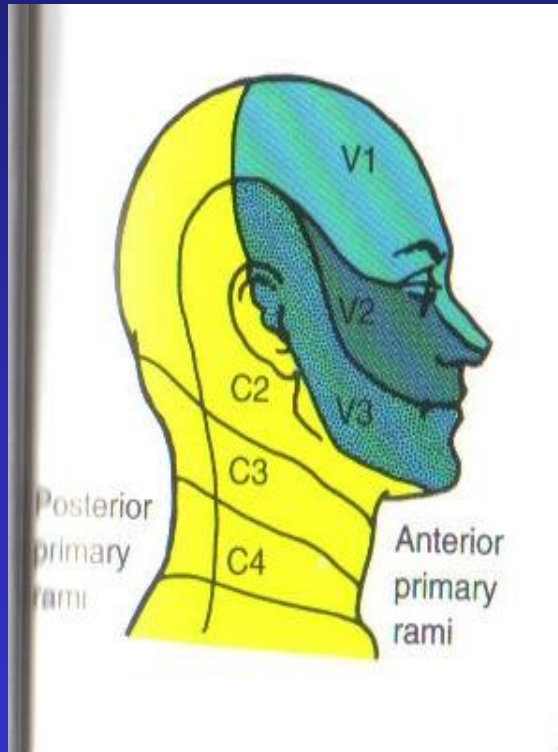
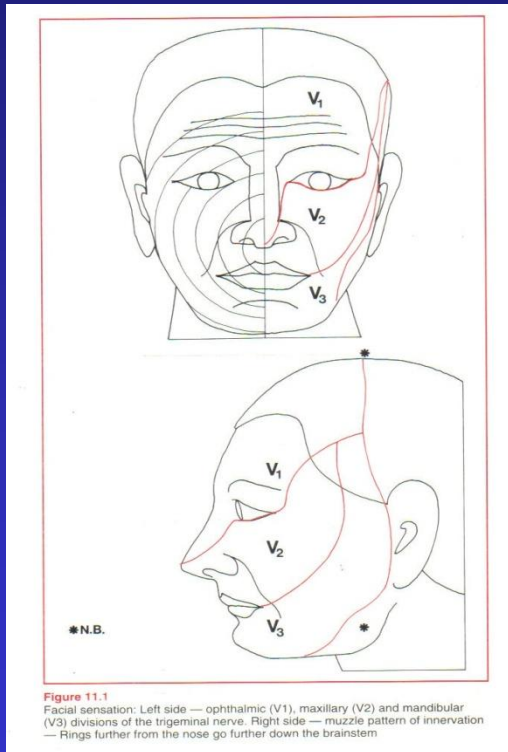


Cranial Nerve 5

- Trigeminal nerve:
 - Sensory: Check deficits to light touch, pinprick, and temperature (face, eye, tongue, partly oropharynx)
 - V1: Forehead
 - Also check corneal reflex: light touch to the cornea with a cotton wisp
 - V2: Cheek
 - V3: Chin
 - Motor: Checking for asymmetry of lateral jaw movements (jaw deviates to the paralyzed side, medial and lateral pterygoid muscles move the jaw from side to side)



V1, 2, 3 and C2, 3 Sensory Distribution (Controversial of C2 and C3 Dermatome)



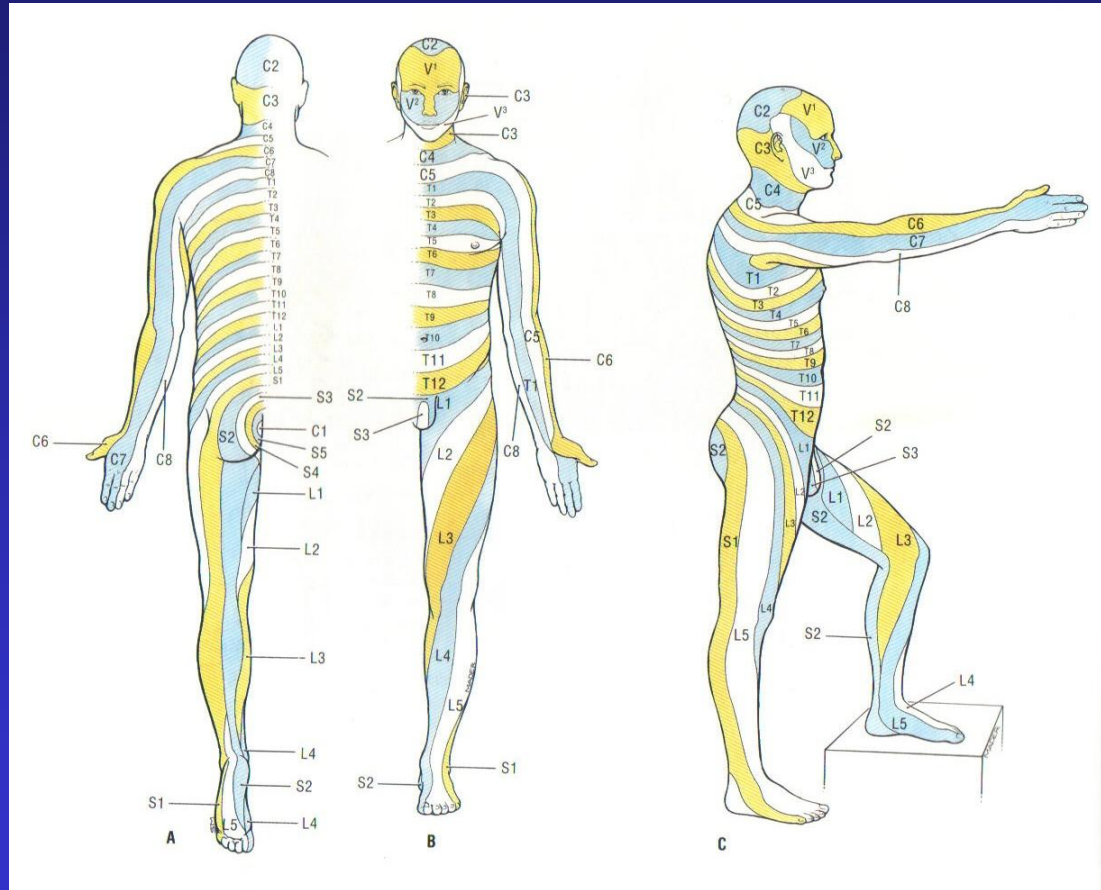
David L Brown. Atlas of Regional Anesthesia. 1999,
page 137 & 181



Property of Chonghao Zhao, MD, PHD



V1, 2, 3 and C2, 3 Sensory Distribution (Controversial of C2 and C3 Dermatome)

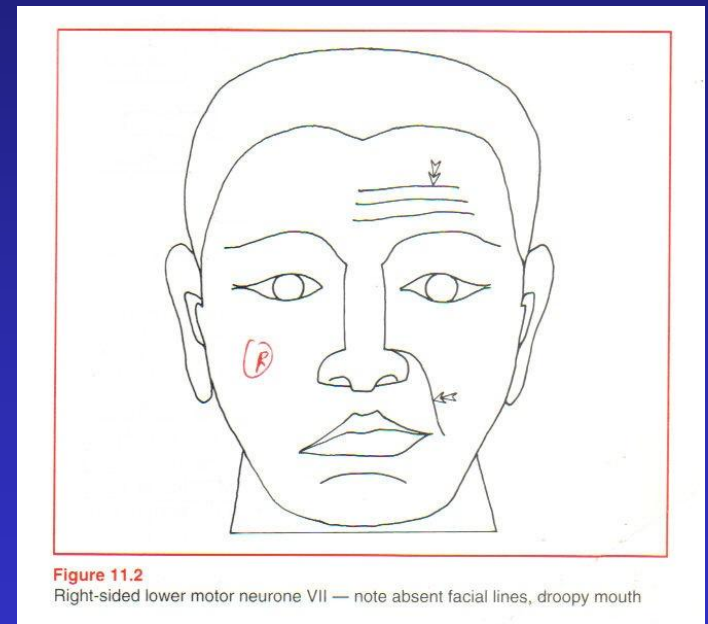


Property of Chonghao Zhao, MD, PhD
Anne M. R. Agur, Grant's Atlas of Anatomy, 1991, Page 252.



Cranial Nerve 7

- Facial nerve:
 - Facial muscle: ask the patient to raise the eyebrows, close the eye, bare the teeth



- Taste: anterior 2/3 of tongue (Bell's Palsy)



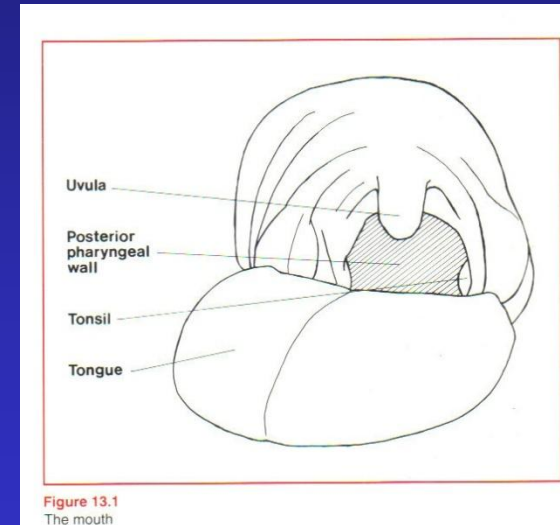
Cranial Nerve 8

- Vestibulocochlear nerve:
 - Balance: in benign positional vertigo, meniere's disease
 - Hearing (use 512 Hz tuning fork):
 - Weber's test: striking the tuning fork and placing it against the middle of the forehead
 - Conductive deafness: lateralization to the **affected** ear, middle ear.
 - Sensorineural deafness: lateralization to the **better** ear, inner ear
 - Rinne test: striking the tuning fork and place it on the mastoid process until the tone no longer being heard, then place it over the external auditory meatus
 - Conductive deafness: not hear the sound over the external auditory meatus (**BC > AC**)
 - Sensorineural deafness: still hear the sound over the external auditory meatus (**AC > BC**)



Cranial Nerve 9 & 10

- Glossopharyngeal nerve:
 - Sensation back of tongue, pharynx, middle ear
 - Taste posterior 1/3 tongue
- Vagus nerve:
 - Soft palate muscle: soft palate elevation
 - Ask the patient to say “Ah”
- Gag reflex:
 - CN 9 sensory input
 - CN 10 motor output-Ambiguus nucleus.
 - Lightly touching the posterior oropharynx with a cotton swab
 - May be absent in older patients



Cranial Nerve 11

- Spinal accessory nerve:
 - Sternocleidomastoid muscle: head rotation and tilt to the opposite side
 - Flex and turn the head to each side against resistance
 - Trapezius muscle: shoulder elevation.
 - Shrug the shoulders against resistance



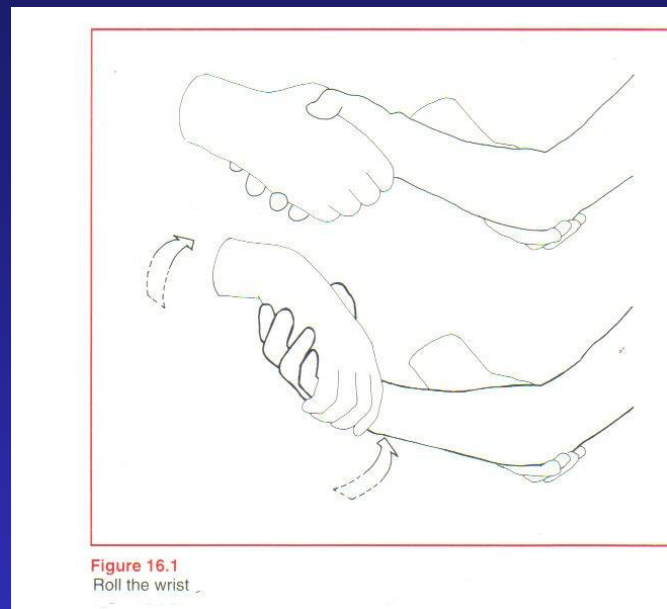
Cranial Nerve 12

- Hypoglossal nerve:
 - Tongue muscle
 - Stick out the tongue
 - Deviate to the weak side
 - Push it into each cheek



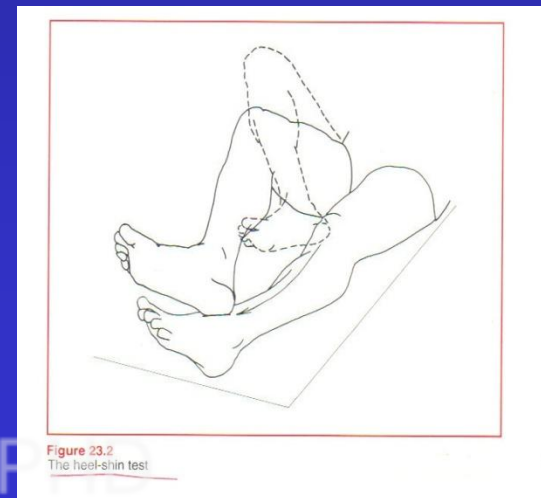
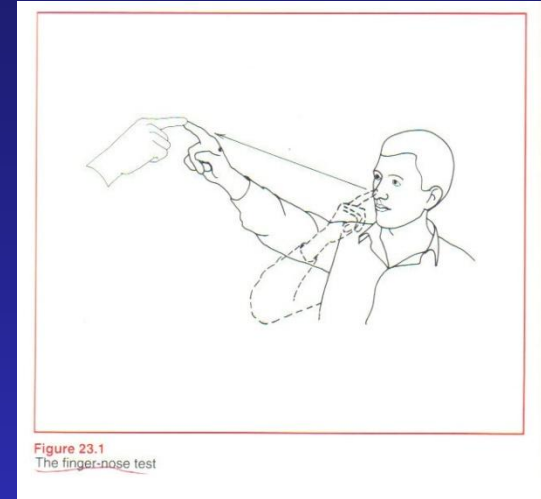
Motor

- Muscular bulk: check atrophy (myopathy)
- Muscular tone: look for spasticity (stroke)
- Muscular strength: grade the strength
 - 0: no muscle contraction visible
 - 1: barely visible muscle contraction
 - 2: active movement of part of limb with gravity eliminated
 - 3: active movement of part of limb against gravity
 - 4: active movement against moderate resistance
 - 4 - : against slight resistance
 - 4+ : against strong resistance
 - 5: normal power



Coordination

- Involving sensory feedback, motor output, integration center (mainly by cerebellum)
- Tests:
 - Finger-to-nose test:
 - Alternatively touch a fingertip to the nose and examiner's finger
 - Heel-to-shin test:
 - Slide the heel up and down the front of the shin



Reflexes – Deep Tendon Reflex

- Striking the muscle tendon with a reflex hammer
 - Increased reflex in upper motor neuron disease.
 - Decreased in lower motor neuron lesion and muscle disease.
 - Grading:
 - 4 + : increase with clonus
 - 3 + : increased without clonus
 - 2 + : normal
 - 1 + : decreased
 - 0 : absent



Bicep, Brachioradialis (Supinator), Triceps Reflex

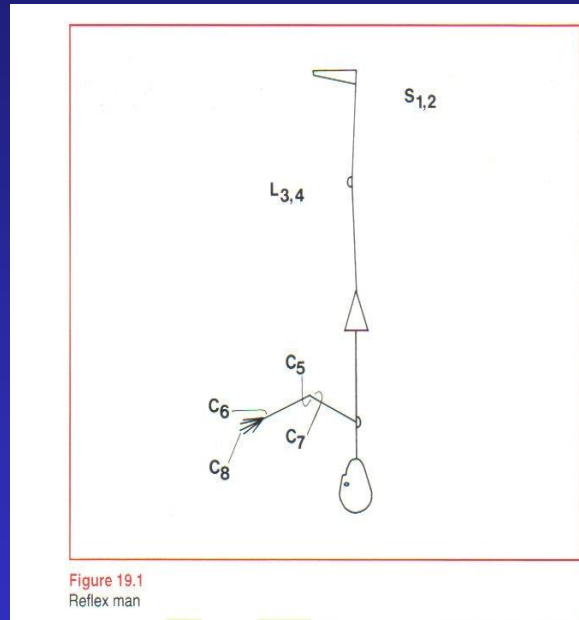


Figure 19.1
Reflex man

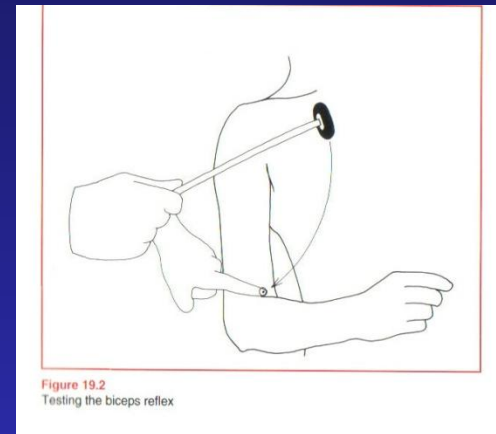


Figure 19.2
Testing the biceps reflex

C5

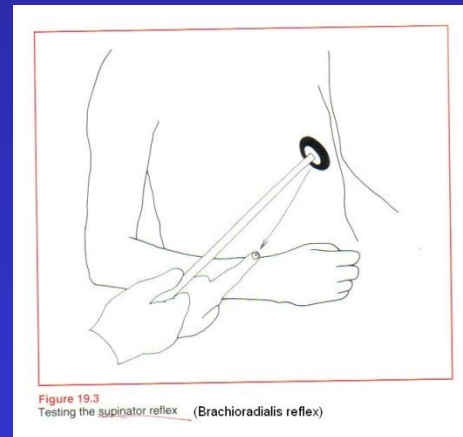


Figure 19.3
Testing the supinator reflex (Brachioradialis reflex)

C6

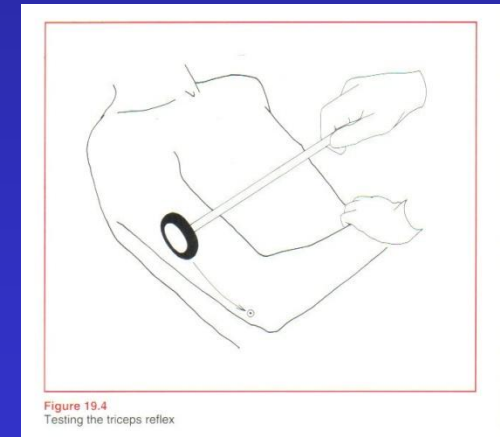
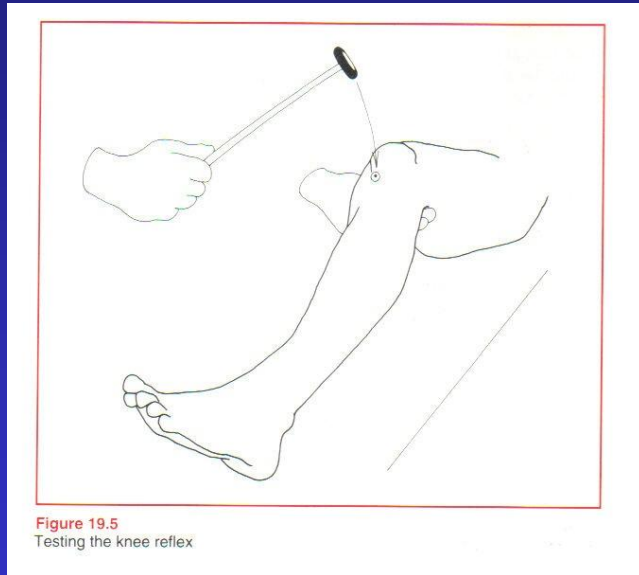


Figure 19.4
Testing the triceps reflex

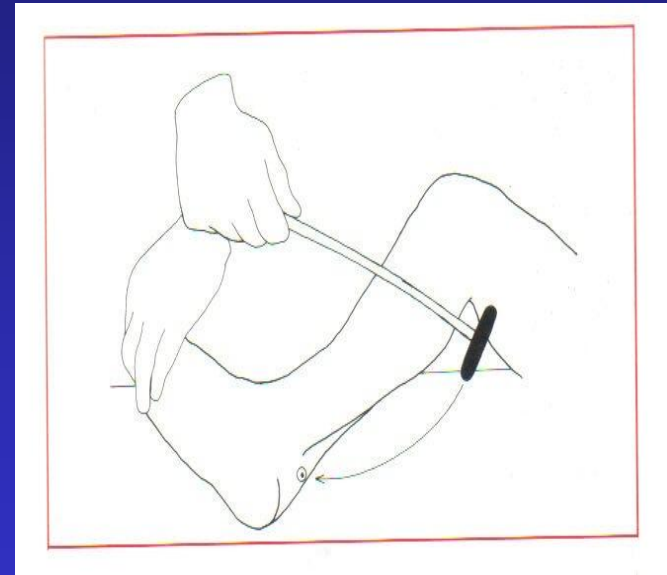
C7



Patellar and Ankle Jerk (Achilles) Reflex



L3, 4



S1, 2

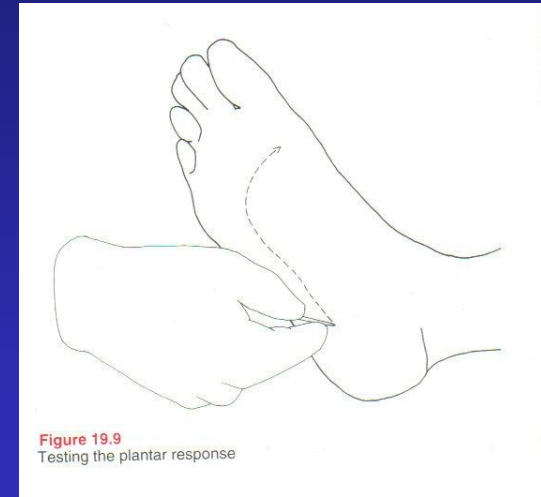


Property of Chonghao Zhao, MD, PHD



Reflexes – Plantar Reflex

- Bakinski's sign (upper motor neuron lesion):
 - Firmly stroke the sole of the patient's foot, beginning at the heel and following up the lateral margin and across the ball of the foot to the base of the big toe
 - Negative: The toes all flex, is flexor plantar response
 - Positive: Big toe extends, the other toes spread, is extensor plantar response
 - No response: no toe movement
 - Profound motor weakness to extend the big toe
 - Sensory abnormality
 - Withdrawal response: If big toe extends, the other toes extend and ankle reflexes, need to repeat test more gently

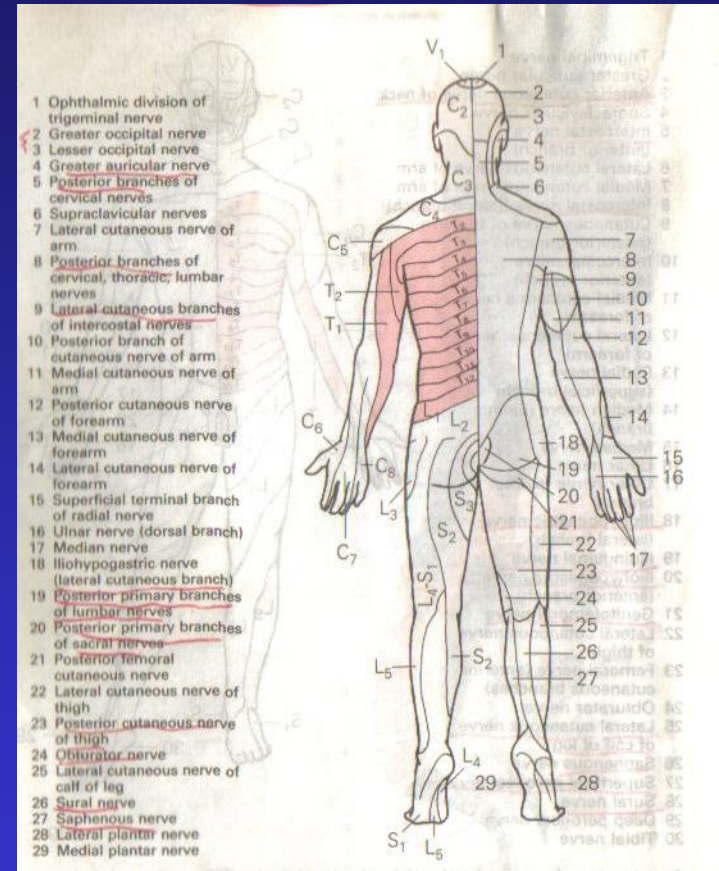
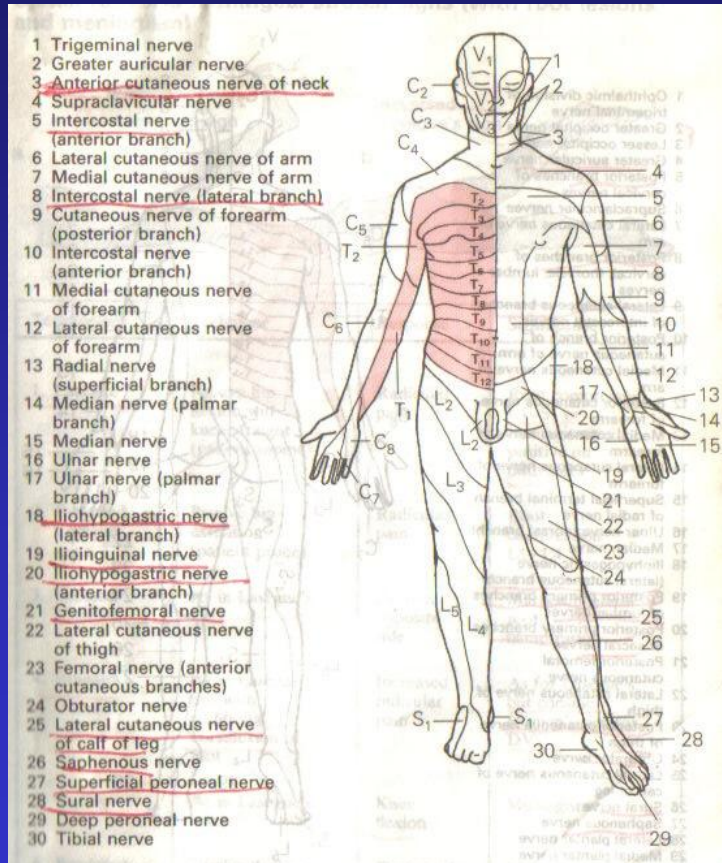


Sensory - Primary Sensory Modalities

- Light touch
- Pinprick
- Temperature
- Vibration (128 HZ)
- Joint position (Proprioception)



Dermatome and Peripheral Nerves



Property of Chonghao Zhao, MD, PHD

真善美



Sensory - Cortical Sensory Modalities

- Graphesthesia:
 - The ability to recognize writing on the skin purely by the sensation of touch.
 - Close the eye and identify a number traced on the palm
 - Positive if cannot identify: contralateral parietal lobe damage, or damage to the dorsal columns pathway at any point between the tested point and the contralateral parietal lobe.
- Stereognosis:
 - The ability to perceive and recognize the form of an object using cues from texture, size, spatial properties, and temperature
 - Close the eye and identify a key, coin, paperclip
 - Test the intact of contralateral parietal lobe, and posterior column



Gait

- Casual walking
- Toe walking: lower extremity strength $> 4/5$
- Tandem gait test: walk a straight line, touching toe to heel
 - To test ataxia, cerebellar dysfunction, drunk driving test
- Romberg's test: stand with feet together and eyes close
 - Loss of joint positional sense:
 - Posterior column: cervical spondylosis, B12 deficiency
 - Peripheral neuropathy
 - Cannot proceed the test if the patient cannot stand and fall with eye open
 - Cerebellar and central/peripheral vestibular syndrome



My Selective Screening Test (4 min)

- M: x 3
- C: I (skip); II (swinging light, field), III & IV & VI (EOM), V (jaw movement), VII (looking up & showing teeth), VIII (finger rubbing), IX & X (Ah, optional gap), XI (shrugging shoulder), XII (tongue movement)
- M: elbow flexion, hip flexion
- C: FTN
- R: biceps, brachioradialis, patellar, achilles
- S: light touch (optional pinprick) to face, hand
- G: casual walking, tandem

Suggested Readings:

- Memorix Neurology by Peter Berlitz, 1996
- Neurological Examination Made Easy by Geraint Fuller, 1995
- Clinical Neurological Neuroanatomy Made Ridiculously Simple, by Stephen Goldberg, 1990

